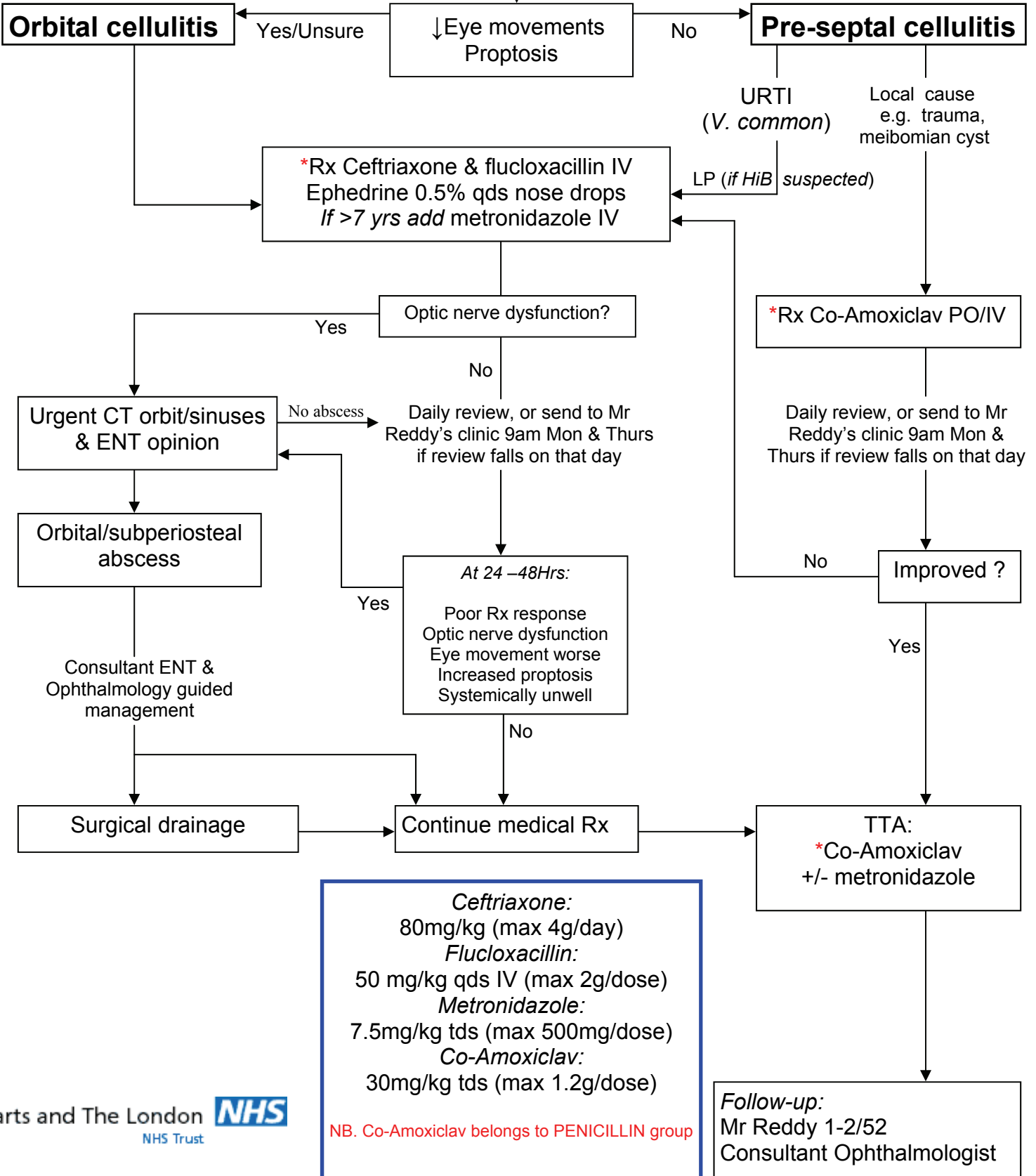


If penicillin/cefalosporin or other betalactam allergy OR if there is a possibility of infection with an antibiotic resistant organism (e.g. MRSA) call microbiologist.

Child with peri-orbital cellulitis

Refer to ophthalmology & paediatric SHOs
Blood cultures & eye swabs



References:

Uzcategui et al. Clinical guidelines for the management of orbital cellulitis. *J Paed Ophthalmol Strab.* 1998; 35(2):73-9
 Uddin JM. Preseptal and orbital cellulitis. In: *Pediatric ophthalmology and strabismus.* Editor Taylor D. London: Saunders; 2004 148-56
 Weiss A et al. Bacterial Peri-orbital and orbital cellulitis in childhood. *Ophthalmology* 1983; 90:195-203
 Management guidelines for orbital cellulitis in children, Mayday Hospital, Croydon (Acknowledgements to Alison Davies)

Care Pathway Consultation group:

Paediatrics: Dr Mustafa; Ophthalmology: Mr Reddy, Mr Coombes, Dr Gore; ENT: Mr Alusi, Mr Wareing; Microbiology: Dr Price; Pharmacy: C. Benn; A&E: D. Simon